

## Quiz: Pacemaker

### Presentation

A routine follow-up twelve-lead ECG (Fig. 1) is performed in a 70 years old male patient implanted with a dual-chamber pacemaker for sick sinus

syndrome two years ago (Model Reply DR, Sorin). The patient is strictly asymptomatic.

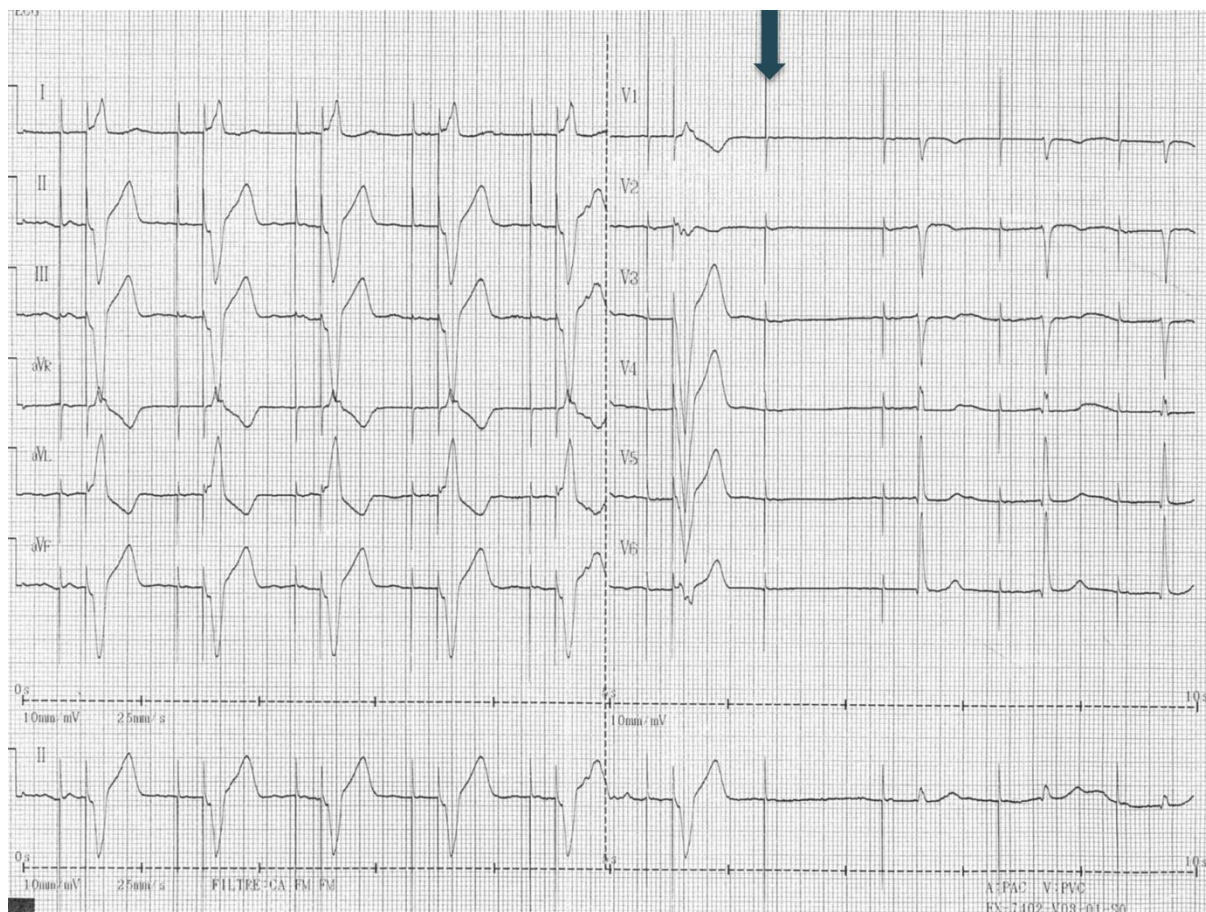


Figure 1. Electrocardiogram tracing

What is the most likely explanation for the 7th beat ?

- 1/ There is an intermittent ventricular pacing dysfunction.
- 2/ There is an intermittent atrial pacing dysfunction.
- 3/ There is no dysfunction.
- 4/ There may be some noise on the ventricular lead.

Sok-Sithikun Bun, Karim Hasni  
Cardiology Department,  
Princess Grace Hospital, Monaco

**Peer-review:** internal

**Conflict of interest:** None to declare

**Authorship:** S.S.B. and K.H. equally contributed to preparation of quiz

**Acknowledgement and funding:** None to declare