

Letter to the Editor

Answer to Letter to the Editor: Multimodality imaging of a left ventricular mass – ECG?

Dear Editor,

We thank author for their attention (1). We will be happy to share the data. Here is electrocardiogram of this patient (Fig. 1).

Sincerely yours,
Sergey Yakovlev

Moscow City hospital named after I.V. Davidovsky,

Moscow, Russian Federation

Peer-review: Internal

Conflict of interest: None to declare

Authorship: S.Y

Acknowledgments and funding: None to declare

References

1. Bacharova L. Letter to the Editor: Multimodality imaging of a left ventricular mass – ECG?. Heart Vess Transplant 2021; 5: DOI: 10.24969/hvt.2021.285

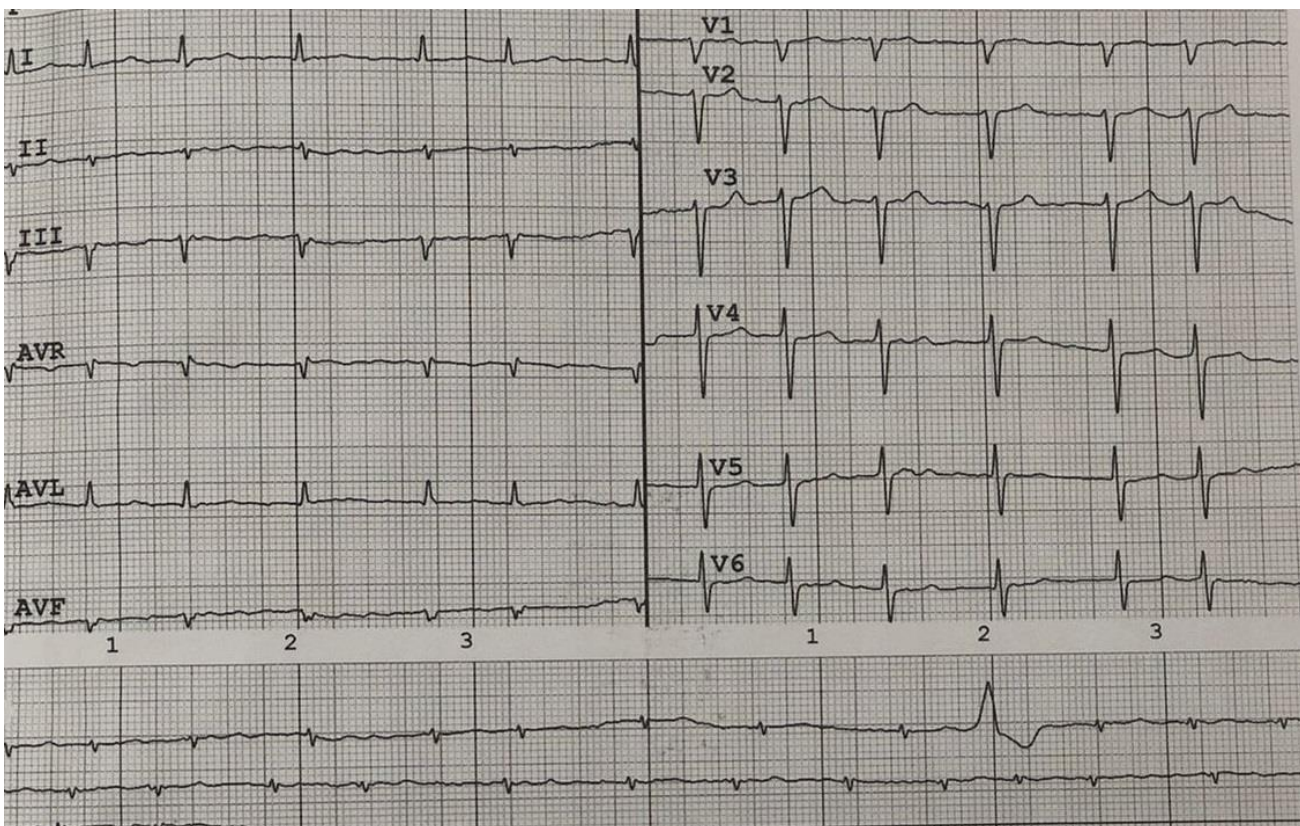


Figure 1. A 12-lead electrocardiogram of a patient

Address for Correspondence: Sergey Yakovlev, Moscow City hospital named after I.V. Davidovsky, Moscow, Russian Federation Email: dr.s.yakovlev@gmail.com Mobile: +79161884244

Received: 12.11.2021 **Accepted:** 13.11.2021

Copyright© 2021 Heart, Vessels and Transplantation

Doi: 10.24969/hvt.2021.286



Night in Bratislava, October 2021. Ljuba Bacharova, Bratislava, Slovakia