

Quiz: Electrocardiogram

Female, 77 years, complains on episodes of lightheadedness and palpitations.

Fragment of ECG was recorded in night-time using 12 leads Holter monitor.

Speed of the recording – 25 mm/s.

The best way to describe these ECG changes is:

- A) Sinus rhythm with second degree atrioventricular block, type II (Mobitz II), atrial extrasystolia
- B) Sinus rhythm with second degree sinoatrial block, type II (Mobitz II)
- C) Sinus rhythm with blocked atrial extrasystole, followed by several escape atrial beats
- D) Sinus arrhythmia, lone atrial extrasystole, right branch bundle block

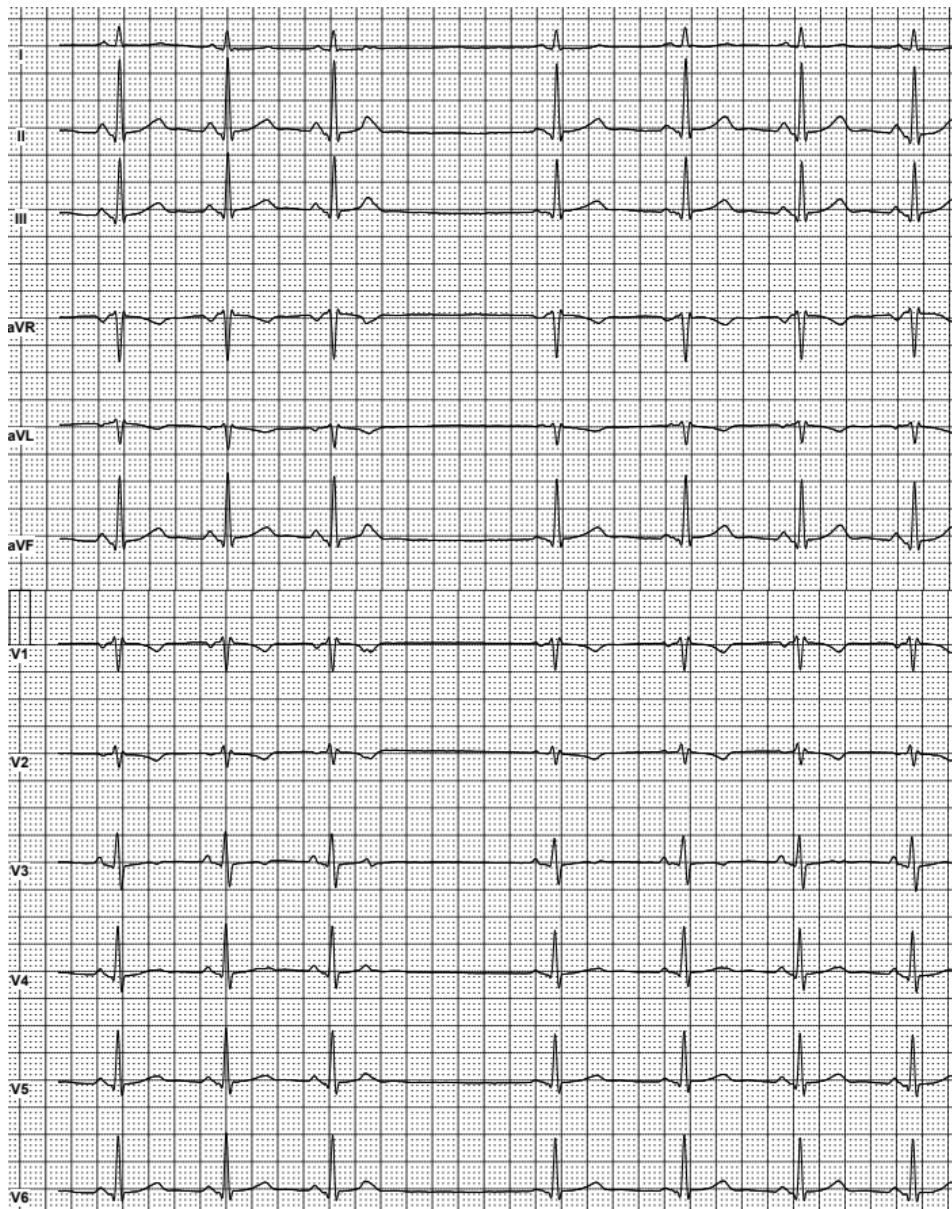


Figure 1. Fragment of multichannel Holter monitoring.

Mykhaylo Sorokivskyy, Lviv Regional Cardiology Center,
Danylo Halytsky Lviv National Medical University, Lviv, Ukraine

Peer-review: Internal; **Conflict of Interest:** None to Declare;

Authorship: M.S. **Acknowledgement:** No funding or material support was received for preparation of the quiz
(answer on page 104)

Address for Correspondence: Mykhaylo Sorokivskyy, Lviv Regional Cardiology Center, Danylo Halytsky Lviv National Medical University, Lviv,
Ukraine **Email:** sorokivskyy@gmail.com

Received 10.12.2017 **Accepted** 10.12.2017 **doi:** 10.24969/hvt.2017.33

Copyright©2017 Heart Vessels and Transplantation