

Answer to Quiz – Electrocardiography

Answer to ECG quiz

Correct answers: D and E

A. **Isorhythmic dissociation** is due to a competition between two different rhythms which rates are very

close, usually a junctional rhythm in competition with slow sinus rhythm. This is not currently the case here. An example of isorhythmic dissociation is provided below (Fig. 1).

LARM HISTORY *BRADY* 19-DEC-2009 06:52:56 HR 24 @25 MM/S

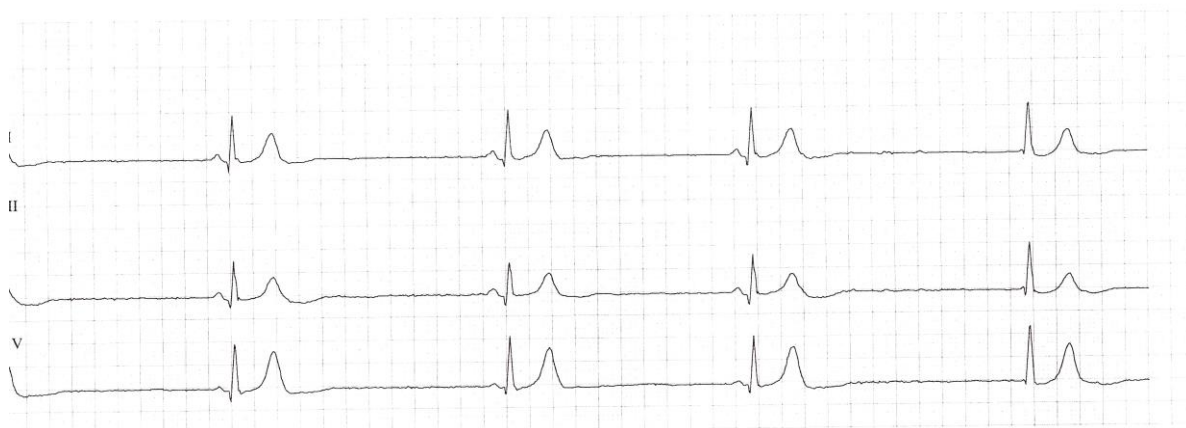


Figure 1. Isorhythmic dissociation

B. Complete atrioventricular block with Hisian extrasystoles - the presence of retrograde p waves excludes the presence of underlying atrial fibrillation with complete atrioventricular block

C. Sinus bradycardia with atrial bigeminy - a sinus P wave should then be visible before each QRS complex, which is not the case here. An example is provided below (Fig. 2).

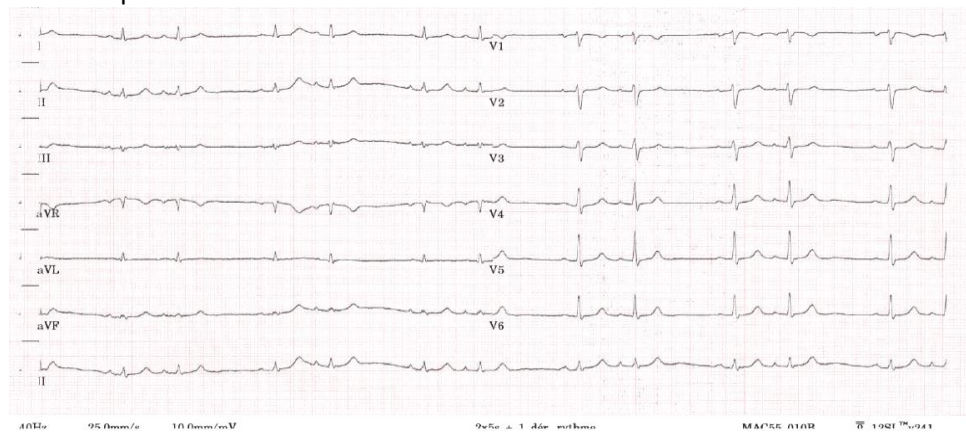


Figure 2. Sinus bradycardia with atrial bigeminy

Address for Correspondence: Sok-Sithikun Bun, Pasteur University Hospital, Nice, France.

Email: sithi.bun@gmail.com Phone: +33492037733 Fax: +37797989732

Received: 04.11.2023 Accepted: 06.11.2023

Copyright ©2023 Heart, Vessels and Transplantation

DOI: 10.24969/hvt.2023.435

D. Junctional escape-capture bigeminy. This is visible in ECG strip below (Fig. 3), the sequence consisting in a group beating of a junctional beat followed by a conducted sinus beat. A normal (anterograde) sinus P

wave (visible here in V1) is sandwiched between 2 QRS complexes an arrangement causing group beating with recurring couplets.

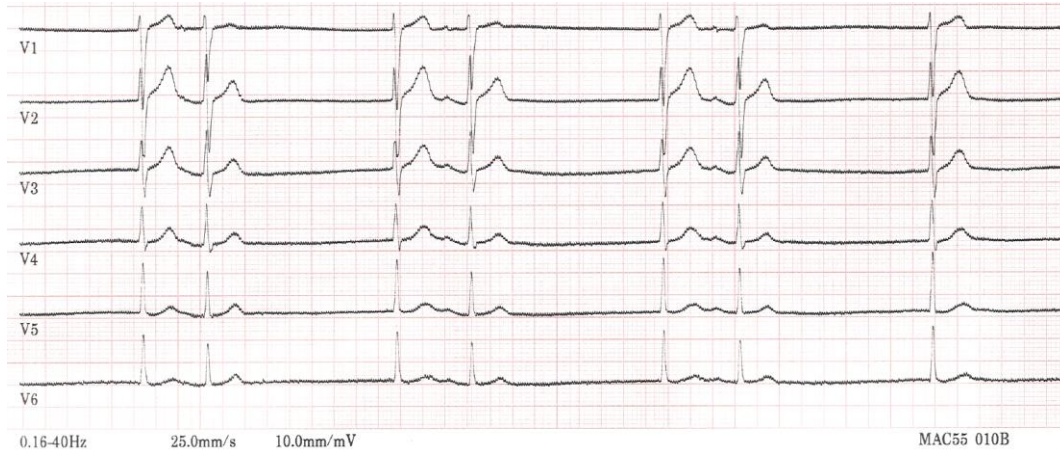


Figure 3. Junctional escape-capture bigeminy

E. Escape-echo bigeminy. This is a variant of the preceding (Fig. 4). The arrangement is different, where a junctional beat gives rise to a retrograde P wave (best

seen in the inferior leads), which is then conducted back to the ventricles, producing a hitherto combination.

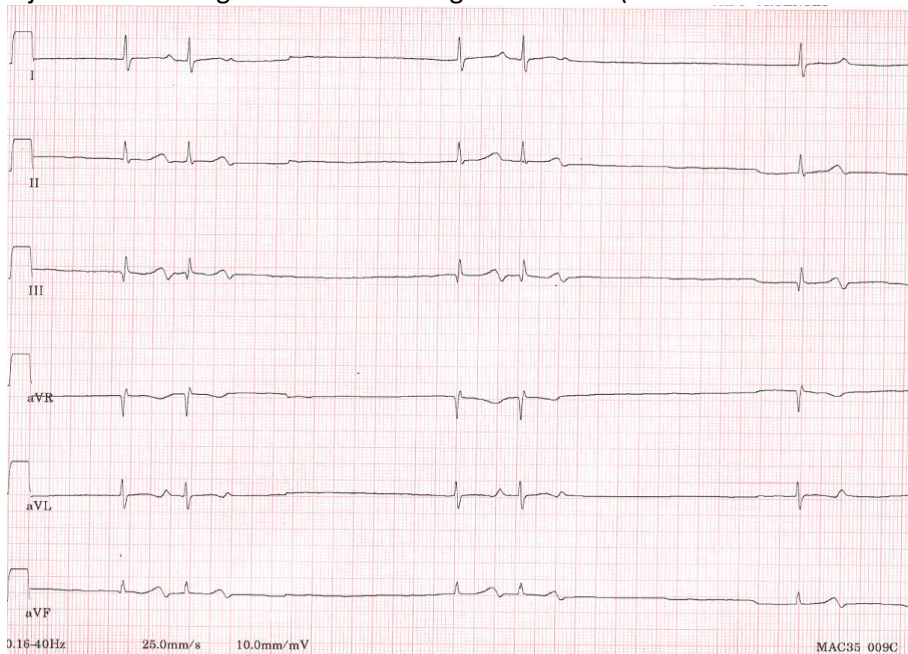


Figure 4. Escape-echo bigeminy

Sok-Sithikun Bun, Didier Scarlatti, Fabien Squara
Pasteur University Hospital, Cardiology Department, Nice, France

Ethics: Informed consent was obtained from patient before all procedures

Peer-review: Internal

Conflict of interest: None to declare

Authorship: S.S.B., D.S., and F.S. equally contributed to preparation of quiz

Acknowledgment and funding: None to declare