

## Quiz: Electrocardiogram

Male, 64 years, presents with an exacerbation of asthma. He is treated with nebulized salbutamol. He has a past history of ischaemic heart disease with percutaneous coronary intervention to the right coronary artery.

Whilst in the emergency department he is noted to have frequent and extensive runs of wide complex tachycardia. The tachycardia is captured on the electrocardiogram below (Fig. 1). The speed of the recording is 25 mm/s.

What is the most likely diagnosis?

- A) Sinus rhythm with left bundle branch block
- B) Ventricular tachycardia
- C) Supraventricular tachycardia with aberrancy
- D) Atrial fibrillation conducted via an accessory pathway

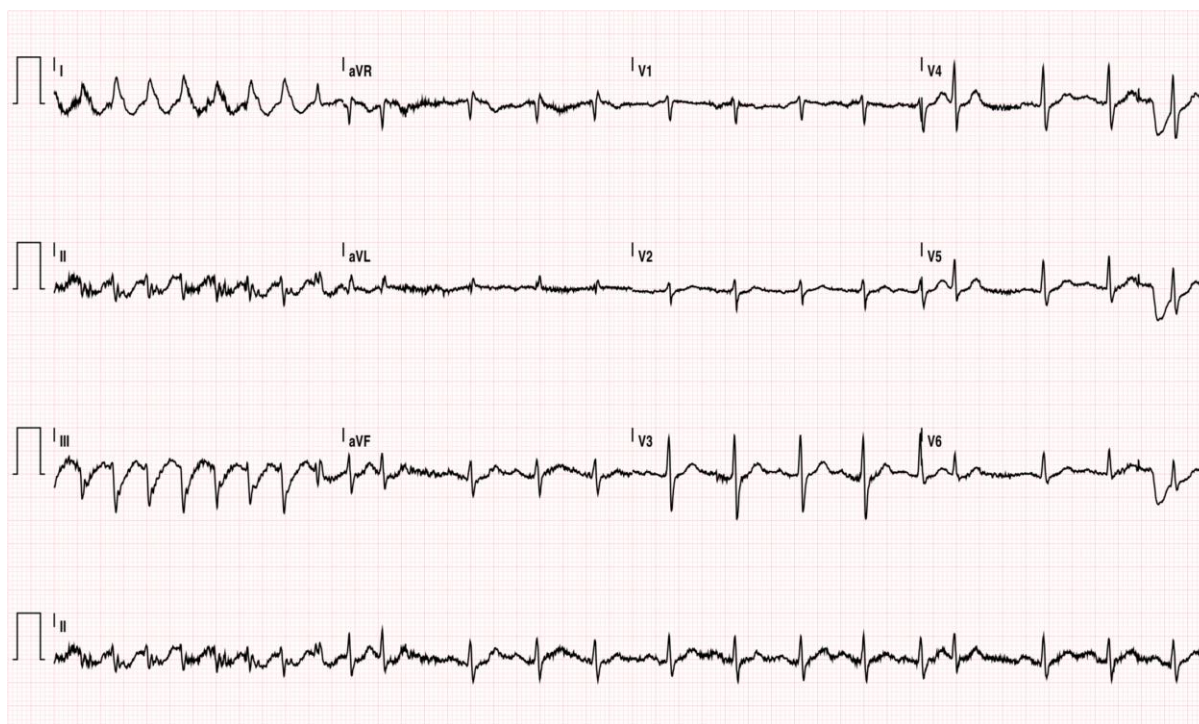


Figure 1. A 12-lead electrocardiogram

Josh Hawson, Jonathan Lipton  
Royal Hobart Hospital, Hobart, Australia

**Peer-review:** Internal

**Conflict of interest:** None to declare

**Authorship:** J.H. and J.L. equally contributed to preparation of quiz

**Acknowledgement and funding:** None to declare

---

**Address for Correspondence:** Jonathan Lipton, Royal Hobart Hospital, Hobart, Australia Email: jonathanlipton@gmail.com

**Received:** 21.08.2019 **Accepted:** 21.08.2019

**Copyright © 2019 Heart, Vessels and Transplantation**

**doi: 10.24969/hvt.2019.139**