

## Quiz: Electrocardiogram

### Presentation

Female, 78 years old, complains on weakness, dizziness, loss of consciousness several times during last week.

Fragment of electrocardiogram (ECG) was recorded using 3 leads Holter monitor at the evening during the rest (Fig.1.).

Speed of the recording – 25 mm/s.

The correct description of this ECG is:

- A) Atrioventricular (AV) block I degree
- B) AV block II degree, Wenckebach
- C) AV block II degree, 2:1
- D) AV block II degree, Mobitz
- E) AV block II degree, advanced
- F) AV block III degree, complete

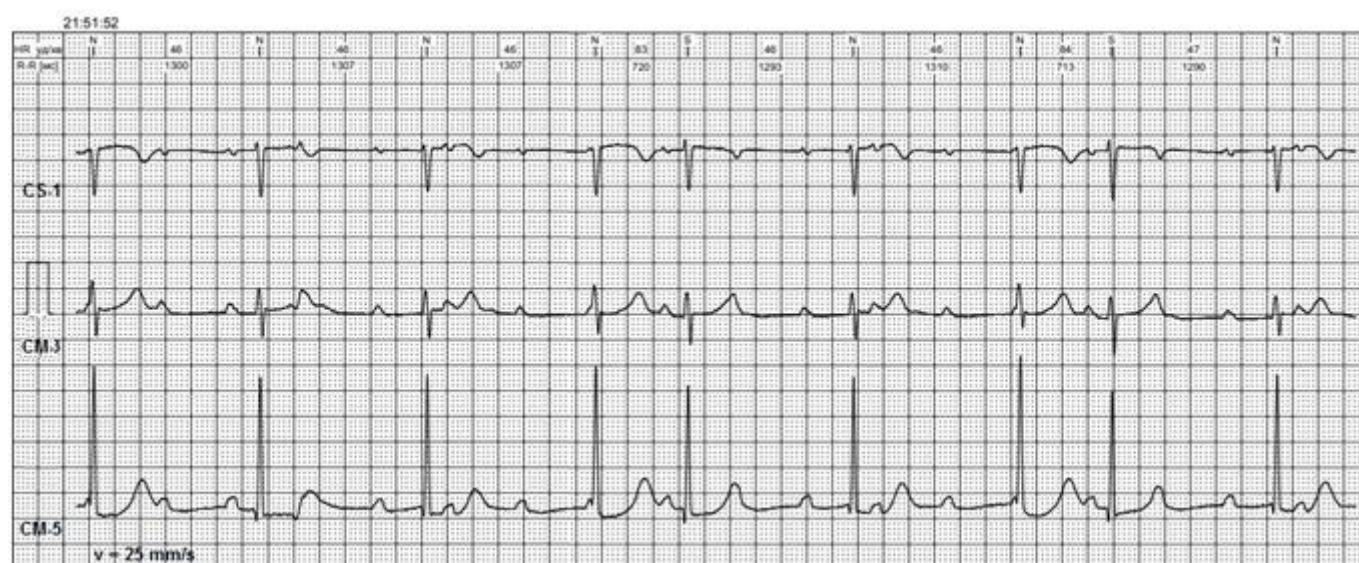


Figure1. Fragment of the 3-channel Holter monitoring

Mykhaylo Sorokivskyy, Ulyana Chernyaha-Royko  
Danylo Halytsky Lviv National Medical University,  
Lviv Regional Cardiology Center, Lviv, Ukraine

**Peer-review:** internal

**Conflict of interest:** None to declare

**Authorship:** M.S. and U.C-R. equally contributed to preparation of quiz

**Acknowledgement and funding:** None to declare

**Address for Correspondence:** Mykhaylo Sorokivskyy, Danylo Halytsky Lviv National Medical University,  
Lviv Regional Cardiology Center, Lviv, Ukraine; Email: msorokivskyy1@gmail.com

**Received:** 14.10.2019 **Accepted:** 15.10.2019

**Copyright© 2019 Heart, Vessels and Transplantation**

**doi:** 10.24969/hvt.2019.161