

Quiz – Electrocardiography

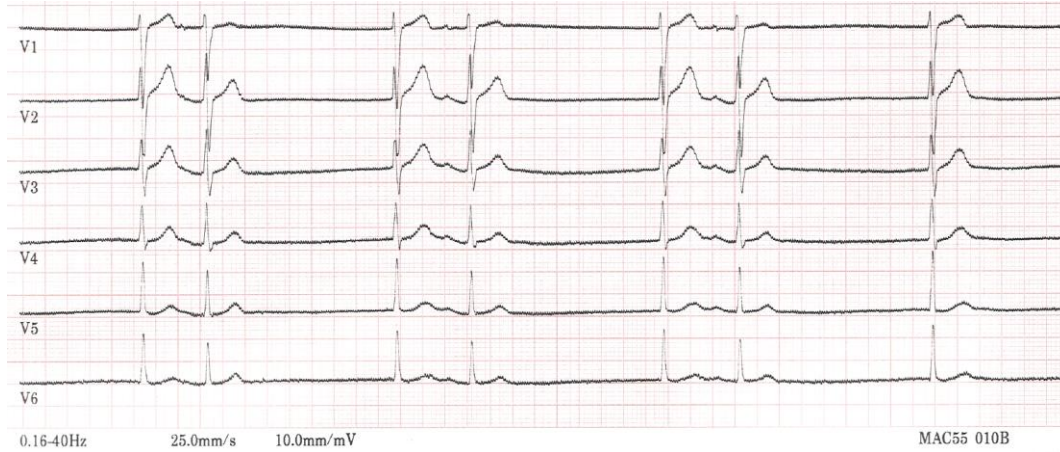
ECG Quiz

We report the case of a 82 year-old female patient, admitted for several episodes of dizziness. The patient

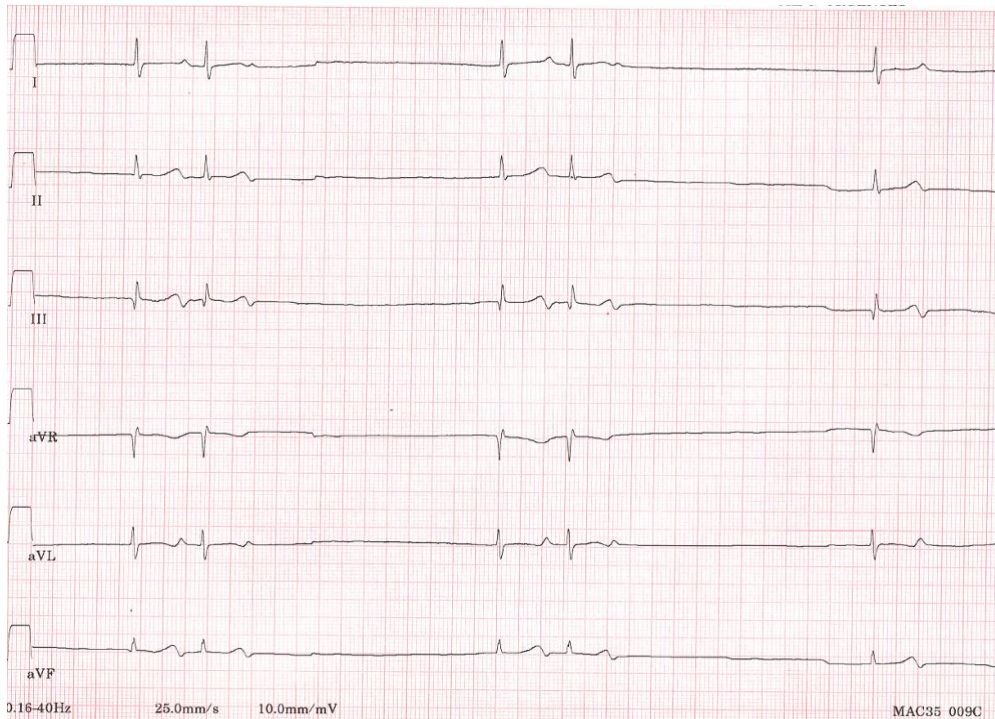
is treated for mild hypertension, without any bradycardic medication.

Two electrocardiogram (ECG) strips are shown below:

ECG strip number 1:



ECG strip number 2:



Address for Correspondence: Sok-Sithikun Bun, Pasteur University Hospital, Nice, France

Email: sithi.bun@gmail.com **Phone:** +33492037733 **Fax:** +37797989732

Received: 04.11.2023 **Accepted:** 06.11.2023

Copyright ©2023 Heart, Vessels and Transplantation

DOI: 10.24969/hvt.2023.434

These tracings show (select correct answer(s)):

- A. Isorhythmic dissociation
- B. Complete atrioventricular block with Hissian extrasystoles
- C. Sinus bradycardia with atrial bigeminy
- D. Junctional escape-capture bigeminy
- E. Escape-echo bigeminy

Sok-Sithikun Bun, Didier Scarlatti, Fabien Squara
Pasteur University Hospital, Cardiology Department,
Nice, France

Ethics: Informed consent was obtained from patient before all procedures

Peer-review: Internal

Conflict of interest: None to declare

Authorship: S.S.B., D.S., and F.S. equally contributed to preparation of quiz

Acknowledgment and funding: None to declare