

Innovations and patents

Method of septal myectomy in the surgical treatment of hypertrophic cardiomyopathy

Kuat B. Abzaliev, Rustem M. Tuleutaev, Symbat A. Abzaliyeva, Roza T. Kuanyshbekova, Elena N. Pakhomenko, Almaty, Kazakhstan
Kazakhstan

Abstract

The invention relates to medicine, namely to cardiac surgery and can be used for surgical treatment of hypertrophic obstructive cardiomyopathy (HOCM).

The technical result of the invention is to provide it the following properties: efficient, fast, and safely performed septal myectomy, in which there is no development of complete block, formation of a defect in the septum and retention of residual stenosis.

The technical result of a method of septal myectomy in HOCM is based on excision through the aortic lumen hypertrophied myocardium of the left ventricular outflow tract, by inserting three needles in the projection of the part interventricular septum to be excised; through the lumen of the middle needle introduce ends of two 3/0 Prolene threads and exit through the lumens of the needles at the edge, where one more thread is inserted, the needles are removed, and the ends of the threads are taken on a tourniquet and pulled tightly, cutting through the thickness of the myocardium with the thread, which allows rapid, safe, reliable and effective septal myectomy without development of complete block and residual stenosis.

Key words: Hypertrophic cardiomyopathy, method of myectomy, invention

(Heart Vessels Transplant 2026; 10: doi:10.24969/hvt.2026.644)

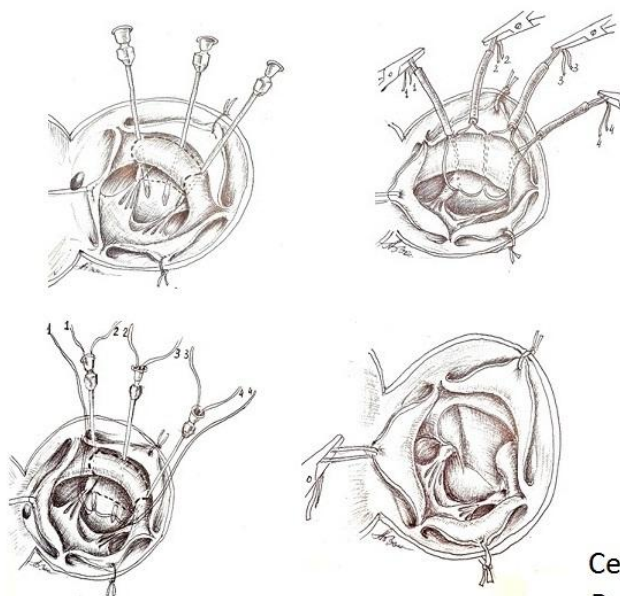
Graphical abstract



Heart, Vessels and Transplantation

Method of septal myectomy in the surgical treatment of hypertrophic cardiomyopathy

Kuat B. Abzaliev, Rustem M. Tuleutaev, Symbat A. Abzaliyeva, Roza T. Kuanyshbekova, Elena N. Pakhomenko, Almaty, Kazakhstan



$$V = \sum_{i=1}^{20} V_i$$

Volume of excision part of myocardium

The use of the proposed method for hypertrophic septal myectomy allows avoiding:

1. Development of complete transverse block, a defect in the interventricular septum or residual gradient in the LVOT.
2. Prolonged time of surgery

Certificate No: 24261 issued on 10.03.2022

Patent No: 36227 issued on 26.05.2023

<http://hvt-journal.com/articles/art464>

doi:10.24969/hvt.2026.644

Address for Correspondence: Kuat B. Abzaliev, Al-Farabi Kazakh National University, Almaty, Kazakhstan

E-mail: kuat.abzaliev@gmail.com

ORCID:

Citation: Abzaliev KB, Tuleutaev RM, Abzaliyeva SA, Kuanyshbekova RT, Pakhomenko EN. Method of septal myectomy in the surgical treatment of hypertrophic cardiomyopathy. Heart Vessels Transplant 2026; 10: doi: 10.24969/hvt.2026.644

Received: 31.03.2026 **Accepted:** 02.04.2026

The invention relates to medicine, namely cardiothoracic surgery and can be used for surgical treatment of hypertrophic obstructive cardiomyopathy (HOCM). Various methods and modifications of septal myectomy are known (1-3).

Despite numerous modifications of this septal myectomy method, residual gradient or complete transverse block remains one of the formidable complications of the operation. The myectomy operation is dangerous because the septal wall is poorly visualized due to limited access through aortic root, which may lead to a high gradient persisting at the left ventricular outflow tract (LVOT), the formation of a defect in the septum with excessive resection and development of complete block. In addition, myectomy is associated with complications such as damage to the aortic and mitral valves, as well as incomplete relief of obstruction due to careless movement of the scalpel. Therefore, the surgeon faces the task of adequate, safe, and rapid resection of the hypertrophied myocardium.

The closest method is the method proposed by Akihiko Usui with coauthors in 2013 (1). He proposed a method of surgical treatment of HOCM, which consists in after opening the ascending aorta inserting three needles into the area of the hypertrophied tissue. One needle is inserted under the middle part of the right coronary leaflet. The second needle is inserted under the commissure between the right and left coronary leaflets of the aortic valve. The third needle is placed between the two previous ones. The needles are withdrawn into the left ventricular cavity, stepping back 2-3 mm from the fibrous ring of the aortic valve, and then the needles are stabilized with Kocher clamps. Resection of the hypertrophied tissue is performed in one block along the three needles from the aortic valve ring toward the apex of the left ventricle. Known septal myectomy methods have shown their effectiveness but require careful and gradual resection of the hypertrophied portion of the interventricular septum (IVST) using a scalpel, which can lead to the development of a complete transverse block, creation of a septal defect, or inadequate myocardial resection and development of residual gradient at the LVOT.

Known septal myectomy methods have shown their effectiveness but require delicate and gradual resection of the hypertrophied part of the IVST using a scalpel, which can lead to the development of a complete transverse block, creation of a defect in the septum or in contrast to insufficient myocardial resection and development of a residual gradient at

the LVOT, which prolongs the operation and leaves the surgeon with doubts. The disadvantages of these septal myectomy methods are that:

1. The method does not guarantee the development of a complete transverse block or LVOT residual gradient.
2. The method leaves doubts and a sense of dissatisfaction in the surgeon.
3. To use known methods of surgery requires a long time to perform the myectomy, to avoid creating a defect in the IVST.

The objective of the invention is to develop a method of septal myectomy by inserting three needles into the area of the hypertrophied IVST in the projection of the presumed resection site and, through the lumen of the middle needle, feed ends of two 3/0 Prolene sutures and pull them out through the lumens of the needles at the edge where one more suture is fed; the needles are removed, and the ends of the sutures are taken on a tourniquet and firmly tightened, cutting through the thickness of the myocardium with the sutures, which allows for fast, safe, reliable, and effective septal myectomy without the development of complete block and residual stenosis.

The technical result of the invention is to confer the following properties: fast, safe, reliable, and effective septal myectomy, prevention of complete transverse block development, IVST defect, and residual stenosis. The method was tested on 15 patients and showed 100% effectiveness, absence of all complications, whereas in the control group moderate residual stenosis (systolic gradient 8-10 mmHg) was observed in 1 patient (6.6%). The stated technical result is achieved by the fact that after the introduction of three needles into the projection of the resected part reliably and effectively perform septal myectomy without the development of complete block and residual stenosis. Thus, septal myectomy is performed efficiently, quickly, and safely, in which there is no development of complete blockade, formation of a defect in the septum, and leaving residual stenosis.

Method of septal myectomy in the surgical treatment of HOCM is depicted in Figures 1- 4.

Description of the method: After inserting three needles into the projection of the IVST part to be excised (Fig.1), into the lumen of the middle needle (Fig. 2) insert the ends of two 3/0 Prolene threads and bring them out through the lumen of the needles at the edge, where another thread is fed, the needles are removed, and the thread ends are taken on a tourniquet (Fig. 3) and pulled tightly, cutting through the myocardium thickness with the thread (Fig. 4).

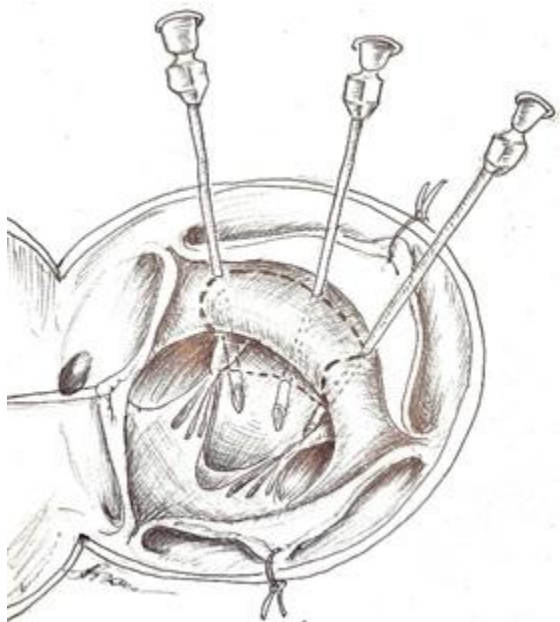


Figure 1. Insertion of three needles into the projection of the IVST part to be excised
IVST – interventricular septum

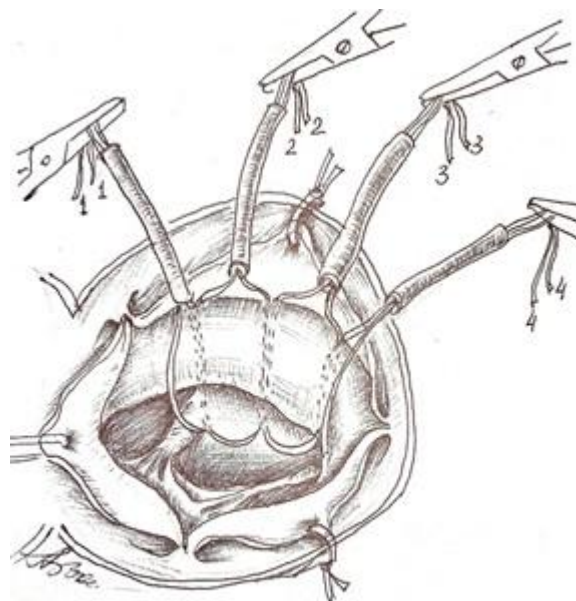


Figure 3. The needles are removed and the thread ends are taken on a tourniquet

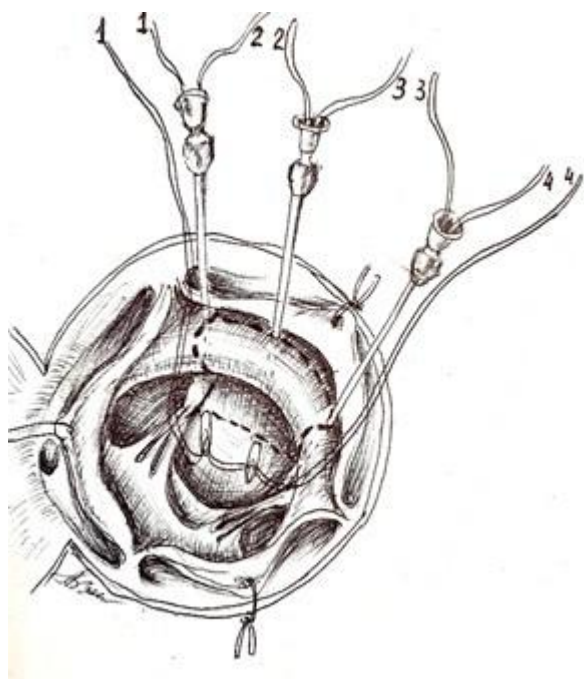


Figure 2. Insertion the ends of two 3/0 Prolene threads into the lumen of the middle needle and bringing them out through the lumen of the needles at the edge, where another thread is fed.

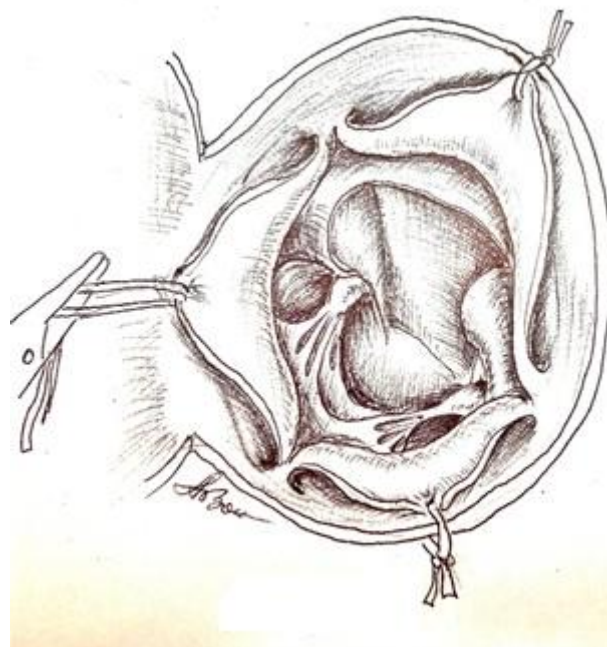


Figure 4. The threads pulled tightly cutting through the myocardium thickness

The use of the proposed method for hypertrophic septal myectomy in surgical treatment of HOCM will allow:

1. To avoid the development of complete transverse block, a defect in the IVST or residual gradient in the LVOT.
2. The method leaves no doubt or dissatisfaction for the surgeon.
3. The procedure does not require a prolonged time to perform the myectomy.

The proposed method permits effectively, quickly, and safely performing septal myectomy.

Formula of the invention

Method of septal myectomy in HOCM by excision through the lumen of the aorta of the hypertrophied myocardium of the LVOT, after inserting three

needles in the projection of the IVST portion to be excised, is characterized by that through the lumen of the middle needle ends of two Prolene 3/0 threads are inserted and exit through the lumen of needles located at the edge, where one more thread is inserted, the needles are removed, and the thread ends are taken onto a tourniquet and pulled tightly, cutting through the myocardium thickness with the thread, which allows rapid, safe, reliable, and effective septal myectomy without development of complete block and residual stenosis.

As the authors we have obtained a certificate of entry into the state register of rights to objects protected by copyright for “Method for calculating the volume and area of septal myectomy in patients with hypertrophic cardiomyopathy and outflow tract obstruction of the left ventricle” No. 24261 dated 10.03.2022 (Fig. 5).



Figure 5. Authors certificate of invention No. 24261 issued on 10.03.2022

In the process of studying pathology on a computed tomography (CT), we obtain images (scans). Using the CT software, we can determine the radius of the hypertrophied part of the IVST (Fig. 6), and we can also draw and measure the line of the proposed excised part.

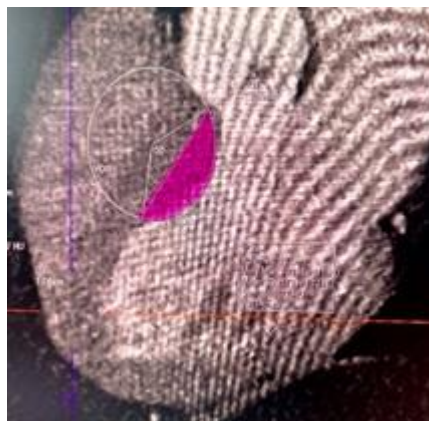


Figure 6. Computed tomography image: Determination of the radius of hypertrophied part for excision

The following Task 1 is set:

- find the area of the unsubtracted part (circle segment) shaded in pink at the condition that the radius (R) of the circle with center at point O and the length of the cut-off segment AB (Fig. 6) are known;
- find the volume of the cut-off body under the condition that the “thickness” of the cut-off segment is 2 cm.

Calculations for the resection of the left ventricular outflow tract part of IVST

For the above example, using the CT scanner software, we have:

$$R = [OA] = [OB] = 3 \text{ cm}; [AB] = 5,5 \text{ cm}$$

The area of the segment is defined by the formula:

$$S_{segment} = S_{sector\ AOB} - S_{triangle\ AOB}.$$

General formula for finding the area using the given data:

$$S_{segment} = \frac{1}{2} R^2 \left(\frac{\pi \cdot \left(\arccos \left(1 - \frac{[AB]^2}{2R^2} \right) \right)}{180^\circ} - \sin \left(\arccos \left(1 - \frac{[AB]^2}{2R^2} \right) \right) \right). \quad (2)$$

Find the volume of the cut-off part by the formula:

$$V = S_{segment} \cdot h,$$

where h is the thickness of the cut-off part.

General formula for finding the volume of the cut-off body:

$$V = \frac{1}{2} R^2 \left(\frac{\pi \cdot \left(\arccos \left(1 - \frac{[AB]^2}{2R^2} \right) \right)}{180^\circ} - \sin \left(\arccos \left(1 - \frac{[AB]^2}{2R^2} \right) \right) \right) \cdot h. \quad (3)$$

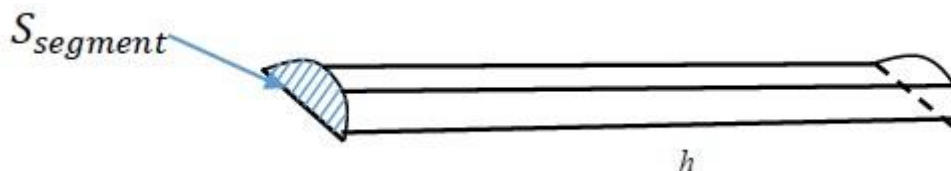
Thus, by substituting the concrete values (1) and h=2 cm into formulas (2) and (3), we obtain the area and the volume of the cut-off body for Task 1:

$$S_{segment} \approx 7,14 \text{ cm}^2$$

$$V = 14,28 \text{ cm}^3$$

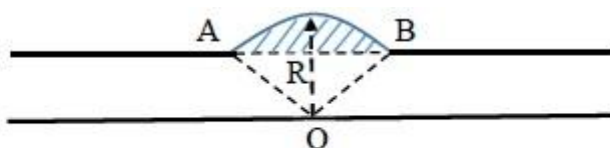
In general, here we considered the simplest model of the shape of the cut-off body, namely the case when

the cut-off part is a cylinder segment with the base area found above and height (thickness) h – given.



Let us consider a less simplified model.

Imagine a CT scan as a sheet of paper with the following picture:

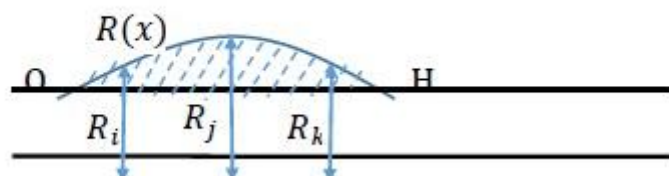


We need to find the area of the excised part in this plane of section – the shaded circular segment. From the scan data, we know the lengths of segments [OA], [OB], [AB]. Above we gave formula (1) for finding the area of such a segment.

obtain a stack of sheets in which the shaded areas form a part of the heart septum that must be excised. The task is to find the volume of this region. In our model considered, above, the excised part represents a segment of a cylinder, i.e., did not change along the entire the radius (thickness) of the excised body.

Next, the CT can perform such scans with a step of 1 mm, i.e. we will have 20 scans, describing the shape of the pathology (assuming its “thickness” is 2 cm). We then use the analogy of a scan with a sheet of paper (or thick cardboard – each sheet thickness 1 mm) with an image. If we stack all scans, we will

Assume that in the cross-sections of the body there are also circular varies, i.e. a certain function. Suppose we obtained the following image (if viewed in the “profile” of the excised part):



where R_i, R_j, R_k - radii of the corresponding sections, and R_x – a function describing the change of the radius.

$$V = \pi \int_0^h R^2(x) dx \quad (4)$$

The volume of the resulting shaded figure representing the excised body can be found in two ways:

Suppose, for example, that the OH curve is a parabola described by the equation

$$R(x) = 1 - (x - 1)^2.$$

- a) Note that the resulting figure is a surface of revolution of the R_x function around the OH axis. In this case the volume of the excised part can be found by the
- b)

Then from formula (4) and with $h=2$ we have:

$$\begin{aligned} V &= \pi \int_0^2 (1 - (x - 1)^2)^2 dx = \pi \int_0^2 (2x - x^2)^2 dx = \pi \int_0^2 (4x^2 - 4x^3 + x^4) dx = \\ &= \pi \left(\frac{4x^3}{3} - x^4 + \frac{x^5}{5} \right) \Big|_0^2 = \pi \left(\frac{32}{3} - 16 + \frac{32}{5} - 0 \right) = \frac{16\pi}{15} \approx 3,35 \text{ cm}^3; \end{aligned} \quad (5)$$

c) We have 20 scans corresponding to the excised area. Take the first scan - according to the algorithm described above, we find the area of the first segment, multiply it by the scan step (say, 1 mm), obtaining some volume V_1 and, the same is done with the second scan – we will obtain V_2 , etc.

Next, we will sum up to obtain the volume of the entire part to be excised:

$$V = \sum_{i=1}^{20} V_i$$

Thus, we built mathematical models described by formulas (4) and (5) for calculating the area and volume of the excised part in pathology for the case when the excised body is a shape of rotation.

The indicated models can be used in further research on constructing mathematical models for septal myectomy in patients with hypertrophic cardiomyopathy and outflow tract obstruction and other pathologies in surgery, when using and constructing computer 3D models in medicine. The examples discussed can also be used to create computer programs to assist surgeons in calculating parameters of the excised part – area, volume, mass. The authors also filed and applied for an invention

patent and received patent No. 36227 dated 26.05.2023.

Peer-review: Internal

Conflict of interest: None to declare

Authorship: K.B.A., R.M.T., S. A. A., R.T.K., and E. N.P equally contributed to the preparation of manuscript and thus fulfilled authorship criteria

Acknowledgements and Funding: None to declare.

Statement on A.I.-assisted technologies use: Author stated they did not use artificial intelligence (A.I.) tools for writing manuscript

Data and material availability: Does not apply

References

1. Usui A, Araki Y, Oshima H, Ueda Y. Needle stick technique for septal myectomy for hypertrophic obstructive cardiomyopathy. *Ann Thorac Surg* 2013;95:726–8)
2. Spiridonov SV. Surgical treatment of obstructive forms of hypertrophic cardiomyopathy. Available at: URL: <http://cardiolog.org/>
3. Babokin VE, Martakov MA, Zainetdinov EM, Popov MA. Method of surgical treatment of hypertrophic obstructive cardiomyopathy. Patent 2017 RU 2 621 167 C1.